

# Customized Titanium Lattice Structure in Three-Dimensional Alveolar Defect: An Initial Case Letter

Marcus Seiler, DDS<sup>1</sup>

Peer W. Kämmerer, MD, DDS, PhD, MA<sup>2</sup>

Michael Peetz, PhD<sup>3</sup>

Amely G. Hartmann, DDS<sup>1,\*</sup>

## INTRODUCTION

For some patients, dental implants would not be an option without horizontal or vertical bone augmentation. Alveolar bone defects may be treated with various bone regeneration techniques including block bone graft, guided bone regeneration (GBR), ridge splitting, and distraction osteogenesis,<sup>1-4</sup> as well as sinus floor augmentation procedures in the upper jaw.

Titanium meshes have been widely used for oral and maxillofacial defect reconstruction in terms of GBR technique.<sup>5-9</sup> They are rigid enough to maintain the grafted space and to avoid soft tissue collapse. Onlay osseous graft protected by a titanium mesh demonstrated significantly less bone resorption compared with an onlay bone graft alone.<sup>10</sup> Titanium mesh is also an alternative to a (resorbable) membrane for ridge augmentation.<sup>11</sup>

With its advantages, such as biocompatibility, corrosion resistance, and thermal effects, a titanium mesh has been proven to be useful in these indications,<sup>12,13</sup> and substantial bone augmentation can be achieved using the titanium construct in conjunction with bone grafting.<sup>11,14</sup> The inherent rigidity of stiff titanium membranes maintains the space needed to allow bone growth.<sup>15</sup> Studies have demonstrated that titanium mesh supports the grafted space and prevents soft tissue collapse.<sup>15,16</sup> However, the clinical outcome of augmentation depends on the type of preoperative bone defect.<sup>17</sup> In addition, titanium mesh has good mechanical strength,<sup>18,19</sup> and it can be shaped readily and fixed with suture or pins with resulting potential space. Titanium fiber mesh has proven to act as a bone regeneration scaffold, even with a thin hydroxyapatite coating of the mesh.<sup>20</sup>

The conventional already established GBR method, which is based on nonindividualized mesh constructs, shows significant disadvantages such as manual cutting, bending, and trimming to achieve the desired shape for implant placement. These steps are time intensive and prolong surgery. Furthermore, the outcome of the mesh frequently does not reflect the entire anatomic characteristics in a satisfactory level.

New bone reconstructive techniques based on guided bone regeneration for localized three-dimensional hard tissue augmentation are discussed.<sup>21,22</sup> These techniques can result in significantly enhanced bone regeneration with minimal patient discomfort.<sup>23</sup> The effectiveness of a customized, three-dimensional, preformed titanium mesh as a barrier membrane for peri-implant alveolar bone regeneration has proven to result in satisfactory bone regeneration.<sup>22</sup> In general, the application of individual digital design and rapid prototyping in the reconstruction of bony defects seems promising.

This case report describes the three-dimensional reconstruction of a posterior mandible segment with the use of an individualized customized titanium lattice structure. After 24 months, clinical, radiologic, and histologic results are presented.

## MATERIALS AND METHODS

### Participant

A 61-year-old healthy woman without any medical history showed a highly atrophied segment of the right lower posterior mandible (#29 and #28). The significant vertical and transversal deficit, as well as the challenging soft tissue situation, made a functionally and esthetically satisfying implant placement impossible (Figures 1 and 2).

### Design and material

After clinical examination of oral hard and soft tissue, radiographic analysis was performed. After the acquisition of cone beam computerized tomography (CBCT) data, the three-dimensional model of the bony defect proved to be an inadequate bony situation for implant placement. Augmentation procedure was planned by using a prefabricated titanium lattice structure (Yxoss CBR, ReOss, Filderstadt, Germany) and graft material. Comprehensive information about the individualized lattice structure, xenogenic allograft, and surgery were provided, and informed consent was obtained. Treatment alternatives such as removable prosthesis were declined by the patient.

The patient-specific lattice structure was designed using computer-aided design/computer-aided manufacturing (CAD/CAM) technology by generating a three-dimensional model of the bony defect after CBCT with minimum artifacts from conventional digital imaging and communication in medicine (DICOM) files. The scan data were transferred and modified by

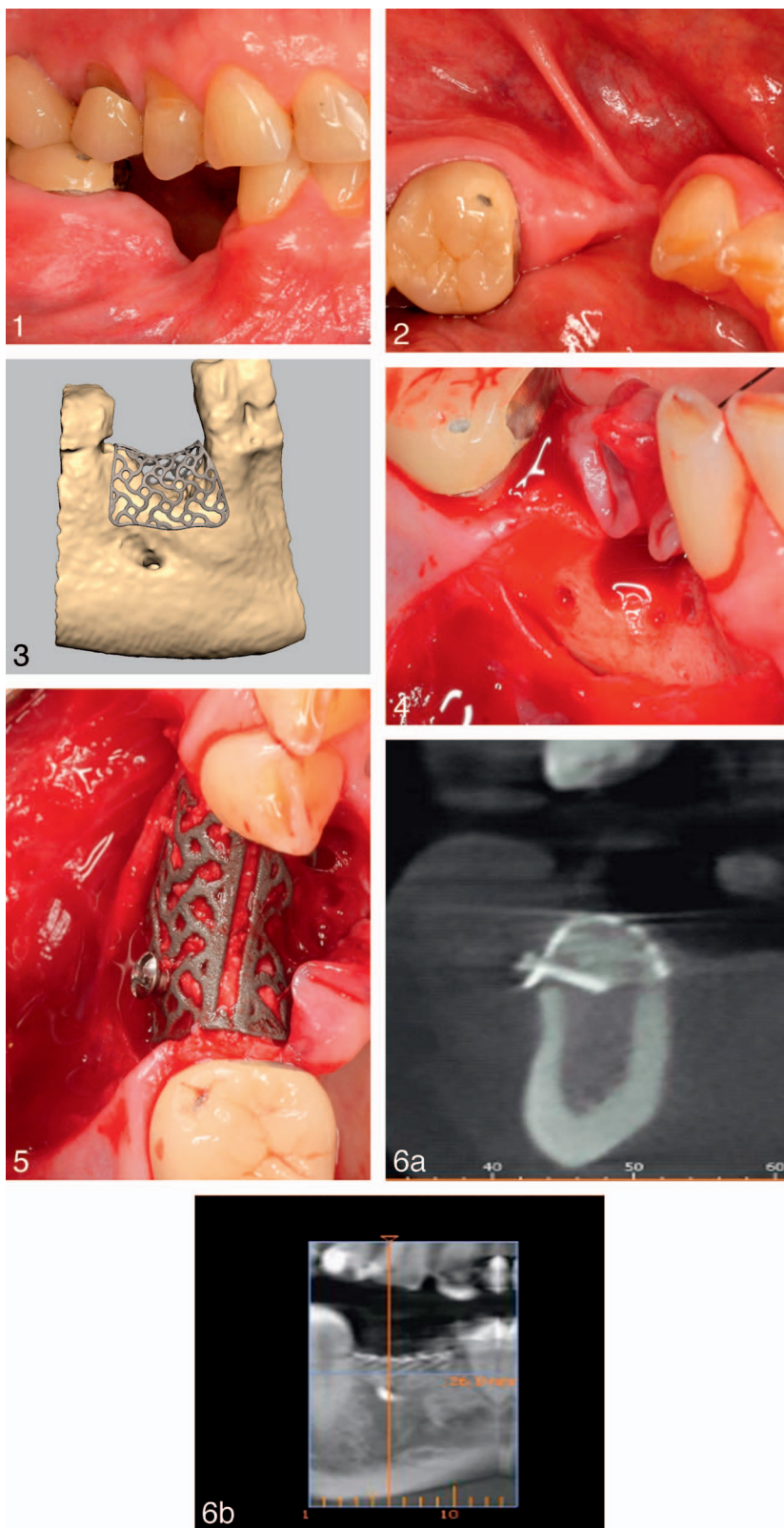
<sup>1</sup> Department of Oral and Maxillofacial Surgery, Private Practice, Filderstadt, Germany.

<sup>2</sup> Department of Oral and Maxillofacial Surgery, University Medical Center of the Johannes Gutenberg University, Mainz, Germany.

<sup>3</sup> Dental Campus, Zürich, Switzerland.

\* Corresponding author: e-mail: amelyhartmann@web.de

DOI: 10.1563/aaid-joi-D-17-00084



**FIGURES 1–6.** **FIGURE 1.** Clinical appearance of the bone defect of the posterior mandible. **FIGURE 2.** The occlusal view shows a severe transversal (and vertical) bone defect together with a challenging soft tissue situation. **FIGURE 3.** Extraction of the three-dimensional surface data from DICOM files reveals the definition of augmentation volume according to prosthetic backward planning. The inner contour of the lattice structure represents the desired augmentation volume. **FIGURE 4.** After marginal preparation of a split flap, a concave bone deficit is shown. Before placing the titanium lattice structure, the cortical bone was perforated with a rose bur. **FIGURE 5.** Titanium lattice structure in situ filled with mixture of alloplastic material and autogenic bone fixed to the bone with one screw. **FIGURE 6.** Sections of the cone beam tomography 6 months after insertion showing a radiologic sufficient amount of augmented bone.

reverse engineering software. The individualized lattice structure was designed according to the desired augmentation volume in the envelope (Figure 3). The final design was approved digitally by the surgeon and then manufactured. Costs depend on size of the defect and subsequent size of the lattice structure.

### Procedure

Surgery was performed under local anesthesia (Ultracain DS Forte, Ultracain, Hoechst, Germany). After elevation of a marginal soft tissue split flap starting in the vestibular gingival mucosa (about 12–15 mm vestibular from the mucogingival junction), scar tissue was removed, and the defect was visualized (Figure 4). The prefabricated titanium lattice structure was inserted with a passive tension-free fit keeping the biological precautions (1.5 mm to the adjacent teeth or nerve structures). Graft material from local bone obtained from the ramus of the mandible was mixed with xenogenic alloplastic material (Bio Oss, Geistlich Pharma, Wolhusen, Switzerland) in a ratio 1:1. Stable fixation of the lattice structure on the residual local bone was achieved by use of one osteosynthesis screw ( $\varnothing$  2 mm/9 mm, Medicon eG, Tuttlingen, Germany) (Figure 5). Wound closure was achieved by suturing without tension. Postoperative instructions such as avoidance of the prosthesis were given to the patient, as well as detailed instructions about oral hygiene.

At suture removal (day 10) and during wound healing, a clinically healthy marginal area and full soft tissue coverage of the customized titanium lattice structure were present.

After a healing period of 6 months, a new CBCT dataset was collected to verify enhancement of the bone augmentation volume (Figure 6) and to plan implant surgery and removal of the lattice structure. For this second surgery, the same local anesthesia was used. After preparation of a mucoperiosteal full-thickness flap, the fixation screw was removed. By applying rotating focus with an elevator at the predetermined breaking point (Easy Removal Design, ReOss) the lattice structure is divided in two parts (Figure 7). The augmented bone volume was of stable dimension, well-vascularized, and without any signs of inflammation (Figure 8). The implant placement was performed following the standard procedures, and a cylindrical bone specimen was gained followed by a tension-free wound closure. The sutures were removed 1 week later.

The implants were functionally loaded after 4 months using a hybrid bridge according to the patient's wishes and preferred concept of the referral practice.

### RESULTS

According to the patient's request, a closure of the interdental gap was necessary to improve the cosmetic and functional outcome. Therefore, an implant placement was required. Alternative treatment options such as conventional prosthetics (bridge #27 to #30 and #31) would have to deal with a wide range and may result in reduced mechanical stability. In this case, the posterior teeth (#30 and #31) were attached to the implant abutment. These teeth needed reconstruction because of an inherent insufficiency of the old crowns (as shown in

Figure 1 compared with Figure 11). To avoid the neighboring healthy tooth being affected (#27), implant placement in region #28 offered the possibility to close the existing gap (#29 and #28).

Twenty-four months after reconstruction, the bone graft appeared well consolidated, and the implants were stable without clinical or radiologic signs of peri-implant bone loss (Figures 9–11). The patient-specific customized titanium lattice structure shaped the area to be augmented by backward planning for the implant position scheduled by the prosthetic need.

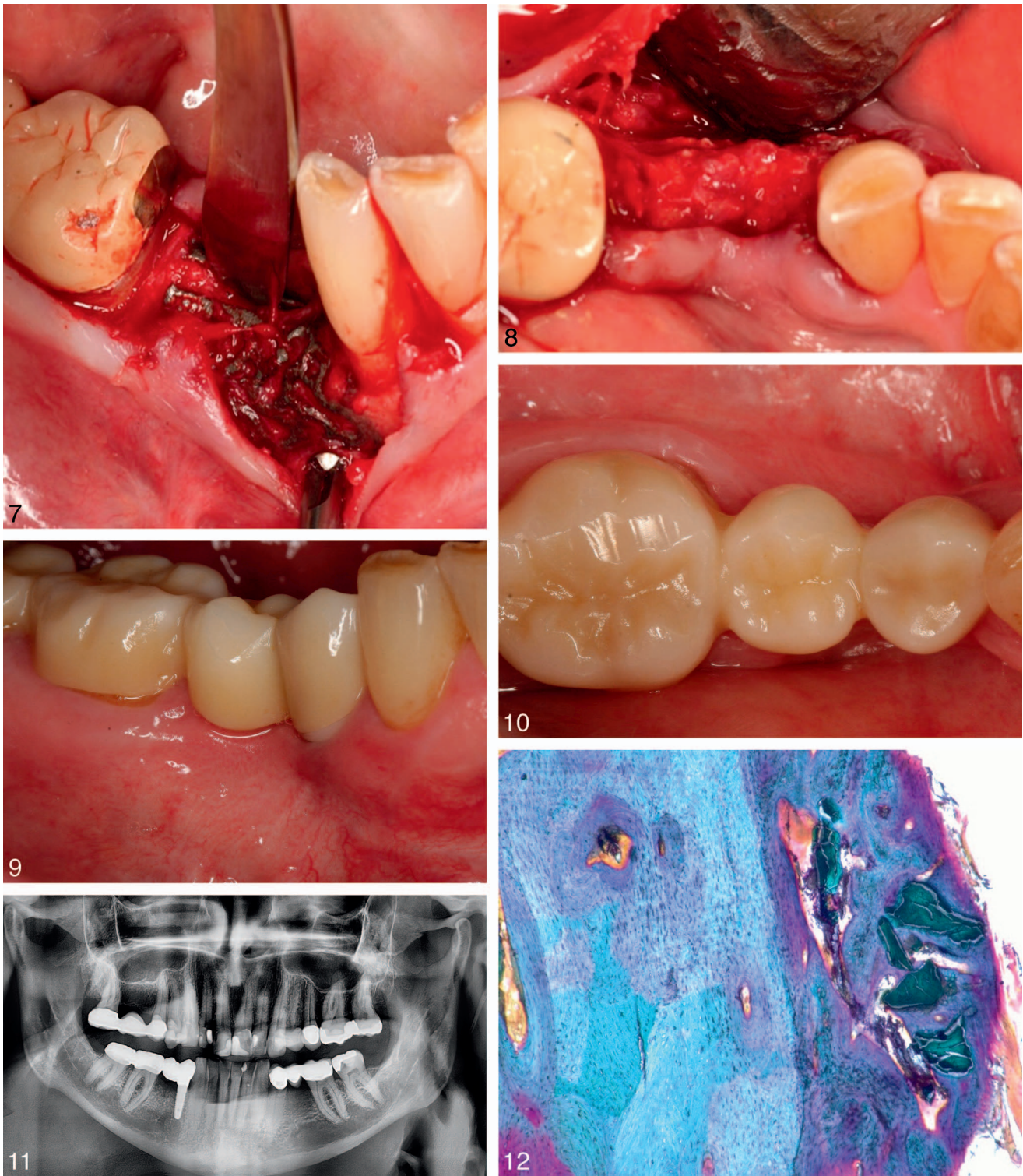
A sample histologic analysis showed newly formed bone including integrated xenogenic bone substitute material particles using toluidine blue staining (Figure 12). Higher magnification revealed newly formed bone tightly adherent to the residual bone plate. Bio-Oss particles appeared in green colors embedded in newly formed bone.

### DISCUSSION

In this case report, a customized patient-specific lattice structure was used for horizontal and vertical augmentation in the posterior mandible. It offered a precise fit and high stability after screw fixation as already proven in recent studies for preformed meshes.<sup>24,25</sup> A customized mesh shortens duration of surgery<sup>26,27</sup> and offers all benefits of reduced time for intervention and improved surgical management,<sup>28</sup> as well as a decreased exposure time to general anesthesia, decreased blood loss, and shorter wound exposure. With its advantages such as biocompatibility, corrosion resistance, and three-dimensional stability, titanium meshes have proven to be useful in the reconstruction and augmentation of oral and maxillofacial defects.<sup>12,13</sup> Studies have demonstrated that the inherent rigidity of stiff titanium mesh supports the grafted space and prevents soft tissue collapse.<sup>15,16</sup> Six months after removal of the mesh, osseous grafts protected by a titanium mesh showed significantly less bone resorption compared with an overlay bone graft alone.<sup>29</sup>

The round and blunt edges of the mesh used in this case prevents mucosal irritation. In the field of implant dentistry, a customized titanium mesh was already proven to be suitable for stabilization of bone regeneration.<sup>30</sup> A recent study proved a printed titanium mesh for alveolar bone reconstruction using a bone morphogenetic protein 2/absorbable collagen sponge 7 (BMP-2/ACS7) allograft to be a possible improvement to hand-configured mesh graft techniques.<sup>31</sup> Ciocca et al<sup>26</sup> prepared a customized titanium mesh to augment the atrophic alveolar ridge and demonstrated satisfactory bone regeneration. A preliminary evaluation of a three-dimensional, customized, and preformed titanium mesh to regenerate alveolar bone proved its efficacy.<sup>22</sup> However, in these protocols, a possible loss of augmentation material in the course of mesh removal may occur. In this case, the removal of the lattice structure caused no fracturing of the augmented bone or damage to soft tissue because of the novel removal function. There were no signs of displacement or compression, and the augmented area showed no resorption processes. Additionally, the time of the second surgery was obviously reduced. Thus, the titanium lattice structure stabilized the defect area and its augmentation





**FIGURES 7–12.** **FIGURE 7.** Removal of the lattice structure through slight extrusion movements by using the preformed slot at the top, dividing the lattice structure at predetermined breaking points. **FIGURE 8.** Clinical situation of the revascularized, augmented transversal region. **FIGURE 9.** Eighteen months after insertion of the implant and 24 months after augmentation with the lattice structure. X-ray shows stable bone reconstruction. **FIGURE 10.** Clinical situation after prosthetic finalization. The occlusal view shows a profound reconstruction of the transversal (and vertical) bone deficit. Soft tissue situation was without scars or inflammation. **FIGURE 11.** Hybrid bridge (posterior teeth #30 and #31 and implant #28) performed by general dentist after 9 months. Vertical dimension of the bone remains stable. **FIGURE 12.** Magnification reveals newly formed bone (darker purple right part) tightly adherent to the residual bone plate (lighter blue staining left). Bio-Oss particles appear in green colors embedded in newly formed bone (right) (toluidine and Masson Goldner, amplification: 400-fold, digital microscope: Keyence VHX-2000D).

material and helped to rebuild the osseous defect to provide enough bone for implant placement procedures. The bony level remained stable even after a longer period, which may be due to the formation of “real new” bone. In addition, histologic examination revealed these new, mature bony structures tightly adherent to the residual bone.

The presented technique included three-dimensional planning and printing, allowing an easy application and convenient removal, together with a stable formation of local bone with no peri-implant bone loss. During the last few years, multiple techniques combining medical imaging and rapid manufacturing techniques<sup>13,27</sup> were published. The two most frequently used rapid prototyping technologies are stereolithography and three-dimensional printing (3DP). 3DP seem to be superior compared with stereolithography because this procedure provides better accuracy and quicker printing time.<sup>28</sup> In the novel protocol at hand, the surgeon is included into the designing process. This modern, digital workflow as part of daily augmentation procedures may result in an improved clinical outcome.

Dental implants bridged to a natural tooth represent a controversial topic in dentistry because of differences in resiliency. A natural tooth's periodontal ligament work as a shock absorber during clenching and chewing. This is not the case for well-osseointegrated dental implants. These differences in resiliency may lead to complications involving tooth eruption, failure of the bridge, fracturing of implant or screw components. Alternatives such as the placement of two implants or other bridge constructions were rejected by the patient.

#### CONCLUSION

This case report presents a novel patient-specific customized lattice structure made of titanium, which is suitable for shaping and rebuilding a bone defect in complex anatomic situations. Clinical and histologic results demonstrated this protocol as a successful and predictable procedure for rebuilding an atrophied bone defect. Further studies are needed to evaluate the effects and benefits of Yxoss CBR.

This protocol provides improved management to facilitate successful surgical augmentation of the jaw bones and provides sufficient quality to improve regeneration of bony defects. It offers a simplified handling, a removal option to keep the augmented bone in place together with reduced handling time. By confirming the design interactively, the surgeon is directly involved in the manufacturing process.

#### ABBREVIATIONS

BMP-2/ACS7: bone morphogenetic protein 2/absorbable collagen sponge 7  
 CAD/CAM: computer-aided design/computer-aided manufacturing  
 CBCT: cone beam computerized tomography  
 CBR: customized bone regeneration  
 DICOM: digital imaging and communication in medicine  
 GBR: guided bone regeneration  
 3DP: three-dimensional printing

#### ACKNOWLEDGMENTS

The authors thank patients, nurses, and physicians for their support with patients' material and reports. Moreover, the authors thank all of our colleagues for helpful discussions. The authors thank Prof Dr Christoph Hämmerle, University of Zürich, for histologic examinations.

#### NOTE

The authors declare that they have no competing interests. M.S. developed the methodology (owner of patent).

#### REFERENCES

1. Misch CM. Comparison of intraoral donor sites for onlay grafting prior to implant placement. *Int J Oral Maxillofac Implants.* 1997;12:767–776.
2. Hammerle CH, Karring T. Guided bone regeneration at oral implant sites. *Periodontology* 2000. 1998;17:151–175.
3. Simion M, Baldoni M, Zaffe D. Jawbone enlargement using immediate implant placement associated with a split-crest technique and guided tissue regeneration. *Int J Periodon Restorative Dent.* 1992;12:462–473.
4. Oda T, Sawaki Y, Ueda M. Experimental alveolar ridge augmentation by distraction osteogenesis using a simple device that permits secondary implant placement. *Int J Oral Maxillofac Implants.* 2000;15:95–102.
5. Simion M, Dahlin C, Rocchietta I, Stavropoulos A, Sanchez R, Karring T. Vertical ridge augmentation with guided bone regeneration in association with dental implants: an experimental study in dogs. *Clin Oral Implants Res.* 2007;18:86–94.
6. Buser D, Halbritter S, Hart C, et al. Early implant placement with simultaneous guided bone regeneration following single-tooth extraction in the esthetic zone: 12-month results of a prospective study with 20 consecutive patients. *J Periodontol.* 2009;80:152–162.
7. Tinti C, Parma-Benfenati S, Manfrini F. Spacemaking metal structures for nonresorbable membranes in guided bone regeneration around implants. Two case reports. *Int J Periodon Restorative Dent.* 1997;17:53–61.
8. Parma-Benfenati S, Roncati M, Galletti P, Tinti C. Resorbable dome device and guided bone regeneration: an alternative bony defect treatment around implants. A case series. *Int J Periodon Restorative Dent.* 2014;34:749–755.
9. Merli M, Moscatelli M, Mariotti G, Rotundo R, Bernardelli F, Nieri M. Bone level variation after vertical ridge augmentation: resorbable barriers versus titanium-reinforced barriers. A 6-year double-blind randomized clinical trial. *Int J Oral Maxillofac Implants.* 2014;29:905–913.
10. Aytac S, Ozbek S, Kahveci R, Ozgenel Y, Akin S, Ozcan M. Titanium mesh fracture in mandibular reconstruction. *J Craniofac Surg.* 2005;16:1120–1122.
11. Her S, Kang T, Fien MJ. Titanium mesh as an alternative to a membrane for ridge augmentation. *J Oral Maxillofac Surg.* 2012;70:803–810.
12. Louis PJ, Gutta R, Said-Al-Naief N, Bartolucci AA. Reconstruction of the maxilla and mandible with particulate bone graft and titanium mesh for implant placement. *J Oral Maxillofac Surg.* 2008;66:235–245.
13. Singare S, Dichen L, Bingheng L, Yanpu L, Zhenyu G, Yaxiong L. Design and fabrication of custom mandible titanium tray based on rapid prototyping. *Med Engineer Physics.* 2004;26:671–676.
14. Rakhmatia YD, Ayukawa Y, Atsuta I, Furuhashi A, Koyano K. Fibroblast attachment onto novel titanium mesh membranes for guided bone regeneration. *Odontology.* 2015;103:218–226.
15. Vrielinck L, Sun Y, Schepers S, Politis C, Van Slycke S, Agbaje JO. Osseous reconstruction using an occlusive titanium membrane following marginal mandibulectomy: proof of principle. *J Craniofac Surg.* 2014;25:1112–1114.
16. Rakhmatia YD, Ayukawa Y, Furuhashi A, Koyano K. Current barrier membranes: titanium mesh and other membranes for guided bone regeneration in dental applications. *J Prosthodontic Res.* 2013;57:3–14.
17. Miyamoto I, Funaki K, Yamauchi K, Kodama T, Takahashi T. Alveolar ridge reconstruction with titanium mesh and autogenous particulate bone

graft: computed tomography-based evaluations of augmented bone quality and quantity. *Clin Implant Dent Relat Res.* 2012;14:304–311.

18. Proussaefs P, Lozada J. Use of titanium mesh for staged localized alveolar ridge augmentation: clinical and histologic-histomorphometric evaluation. *J Oral Implantol.* 2006;32:237–247.

19. Proussaefs P, Lozada J, Kleinman A, Rohrer MD, McMillan PJ. The use of titanium mesh in conjunction with autogenous bone graft and inorganic bovine bone mineral (bio-oss) for localized alveolar ridge augmentation: a human study. *Int J Periodontics Restorative Dent.* 2003;23:185–195.

20. Hirota M, Hayakawa T, Yoshinari M, et al. Hydroxyapatite coating for titanium fibre mesh scaffold enhances osteoblast activity and bone tissue formation. *Int J Oral Maxillofac Surg.* 2012;41:1304–1309.

21. Merli M, Mariotti G, Moscatelli M, et al. Fence technique for localized three-dimensional bone augmentation: a technical description and case reports. *Int J Periodontics Restorative Dent.* 2015;35:57–64.

22. Jung GU, Jeon JY, Hwang KG, Park CJ. Preliminary evaluation of a three-dimensional, customized, and preformed titanium mesh in peri-implant alveolar bone regeneration. *J Korean Assoc Oral Maxillofac Surg.* 2014;40:181–187.

23. Merli M, Moscatelli M, Mazzoni A, et al. Fence technique: guided bone regeneration for extensive three-dimensional augmentation. *Int J Periodon Restorat Dent.* 2013;33:129–136.

24. Cui J, Chen L, Guan X, Ye L, Wang H, Liu L. Surgical planning, three-dimensional model surgery and preshaped implants in treatment of bilateral craniomaxillofacial post-traumatic deformities. *J Oral Maxillofac Surg.* 2014;72:1138 e1131–e1114.

25. Ortorp A, Jemt T. Early laser-welded titanium frameworks supported by implants in the edentulous mandible: a 15-year comparative follow-up study. *Clin Implant Dentistry Relat Res.* 2009;11:311–322.

26. Ciocca L, Mazzoni S, Fantini M, et al. A CAD/CAM-prototyped anatomical condylar prosthesis connected to a custom-made bone plate to support a fibula free flap. *Med Biol Eng Comput.* 2012;50:743–749.

27. Wang G, Li J, Khadka A, Hsu Y, Li W, Hu J. CAD/CAM and rapid prototyped titanium for reconstruction of ramus defect and condylar fracture caused by mandibular reduction. *Oral Surg Oral Med Oral Pathol Oral Radiol.* 2012;113:356–361.

28. Cohen A, Laviv A, Berman P, Nashef R, Abu-Tair J. Mandibular reconstruction using stereolithographic 3-dimensional printing modeling technology. *Oral Surg Oral Med Oral Pathol Oral Radiol Endodontics.* 2009;108:661–666.

29. Rocuzzo M, Ramieri G, Bunino M, Berrone S. Autogenous bone graft alone or associated with titanium mesh for vertical alveolar ridge augmentation: a controlled clinical trial. *Clin Oral Implants Res.* 2007;18:286–294.

30. Ciocca L, Fantini M, De Crescenzo F, Corinaldesi G, Scotti R. Direct metal laser sintering (DMLS) of a customized titanium mesh for prosthetically guided bone regeneration of atrophic maxillary arches. *Med Biol Eng Comput.* 2011;49:1347–1352.

31. Jensen OT, Lehman H, Ringeman JL, Casap N. Fabrication of printed titanium shells for containment of BMP-2 composite graft materials for alveolar bone reconstruction. *Int J Oral Maxillofac Implants.* 2014;29:e103–e105.